



# Chapter 7

## The Muscular System

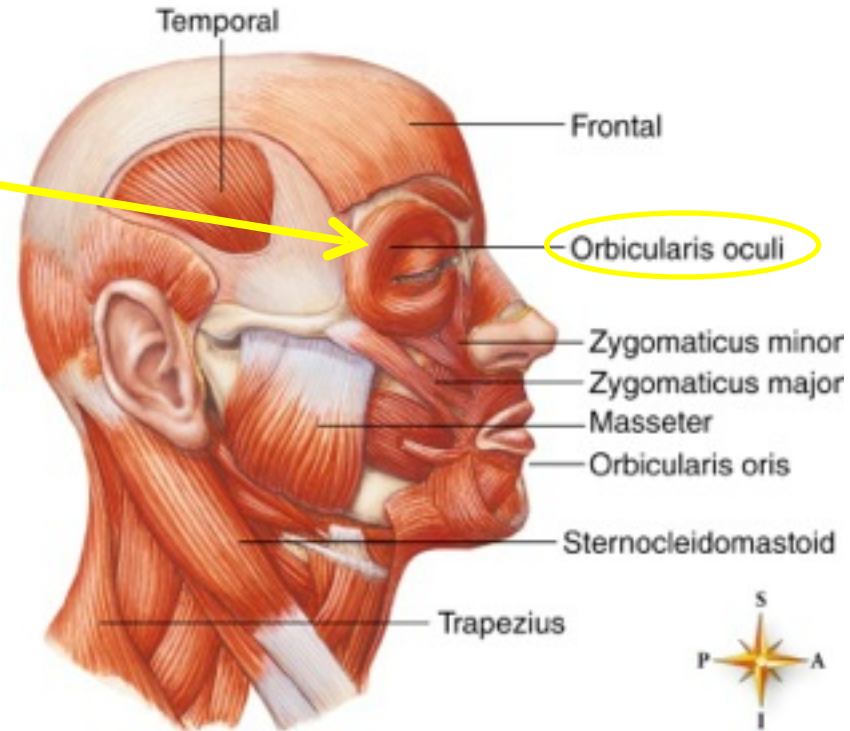


# SKELETAL MUSCLE GROUPS

## A. Muscles of the head and neck

### 1. Facial muscles

- **Orbicularis oculi**
- **Orbicularis oris**
- **Zygomaticus**

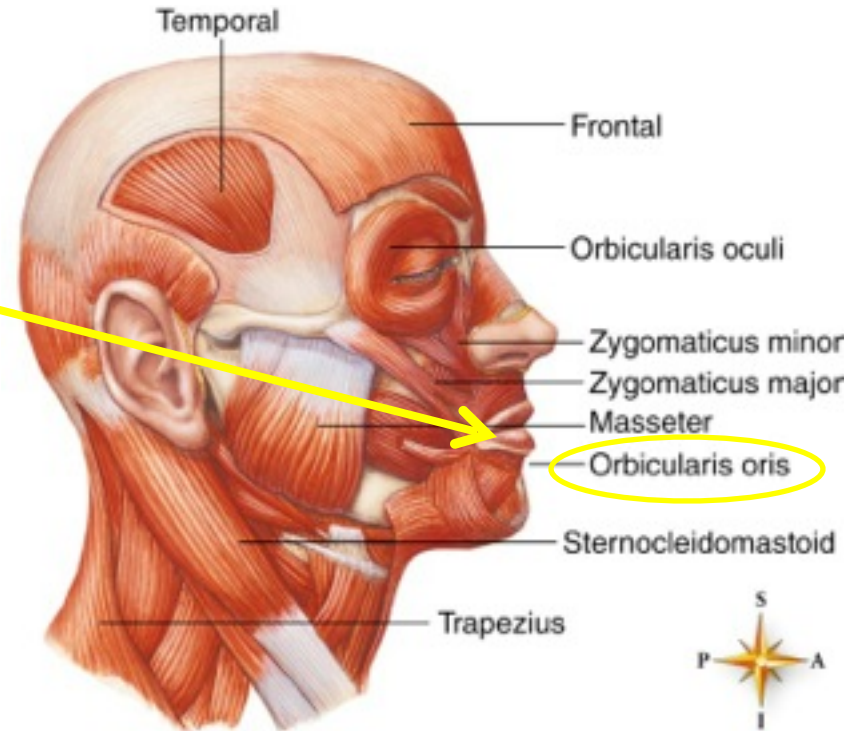


# SKELETAL MUSCLE GROUPS

## A. Muscles of the head and neck

### 1. Facial muscles

- **Orbicularis oculi**
- **Orbicularis oris**
- **Zygomaticus**

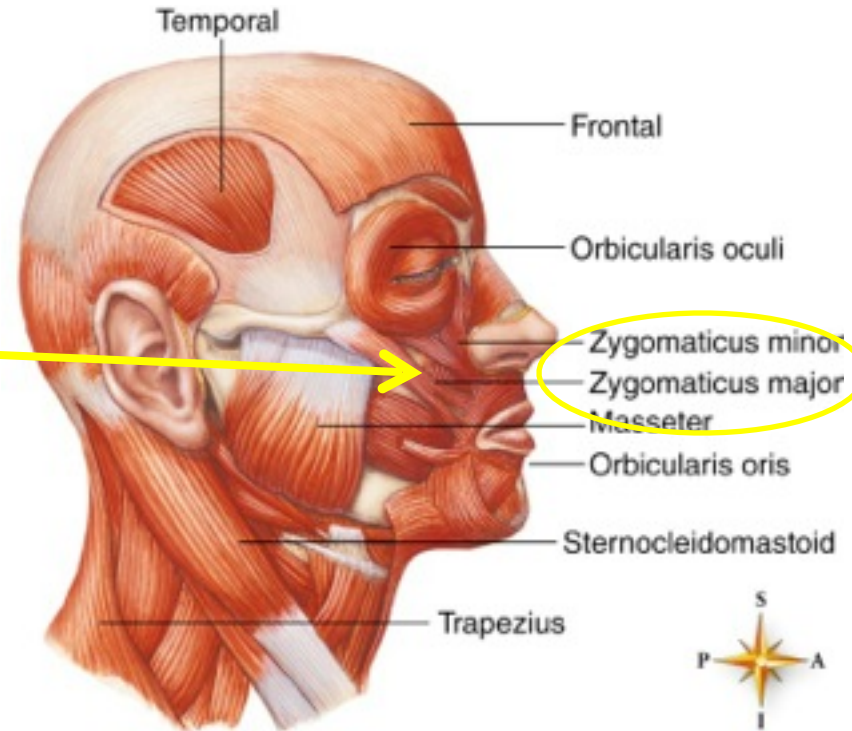


# SKELETAL MUSCLE GROUPS

## A. Muscles of the head and neck

### 1. Facial muscles

- **Orbicularis oculi**
- **Orbicularis oris**
- **Zygomaticus**



# SKELETAL MUSCLE GROUPS

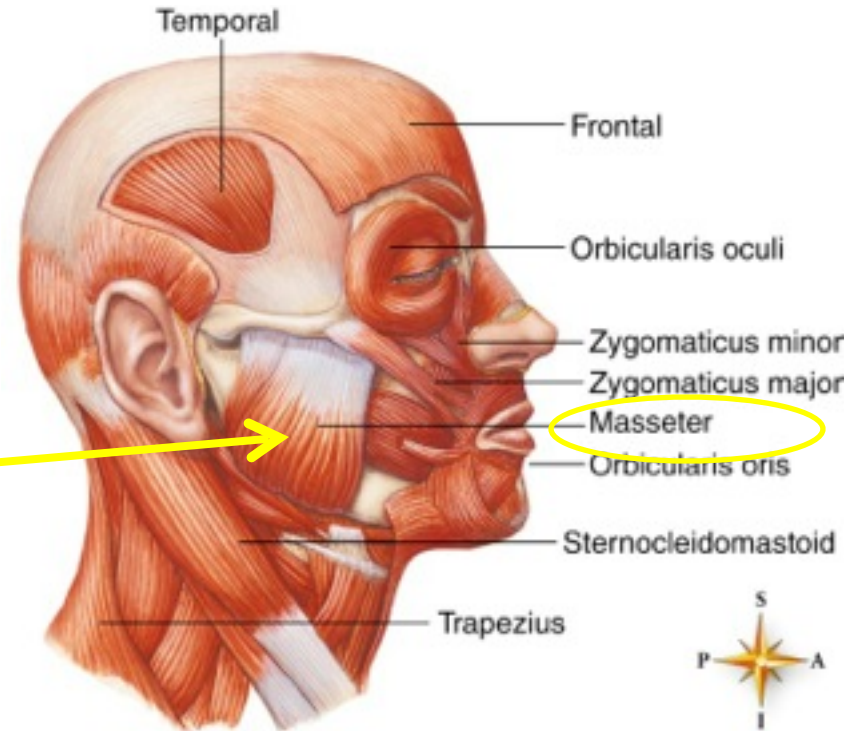
## A. Muscles of the head and neck

### 1. Facial muscles

- **Orbicularis oculi**
- **Orbicularis oris**
- **Zygomaticus**

### 2. Muscles of mastication

- **Masseter**
- **Temporal**





# SKELETAL MUSCLE GROUPS

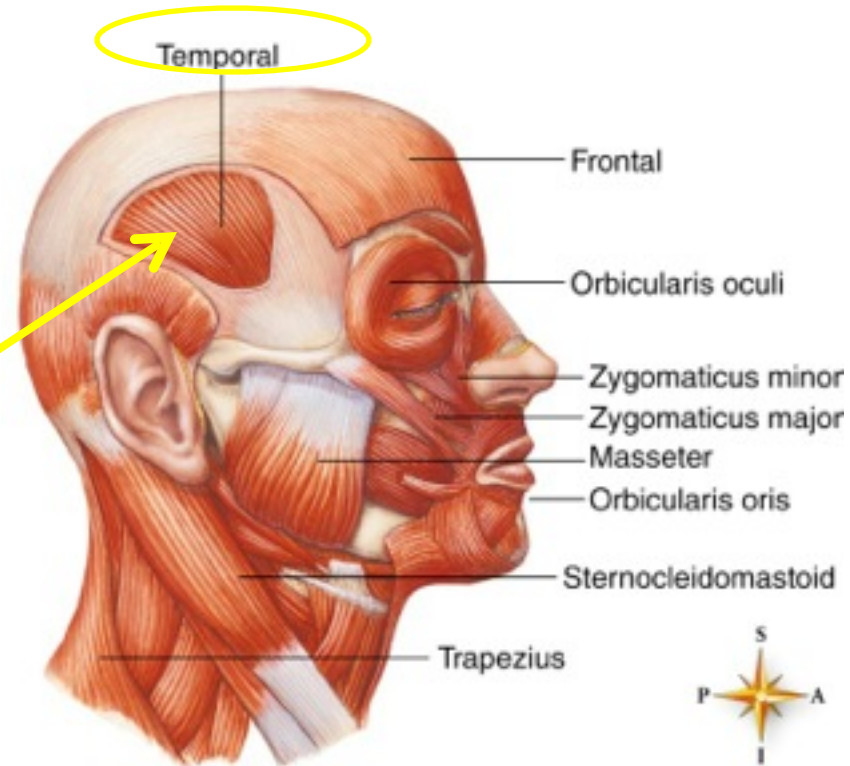
## A. Muscles of the head and neck

### 1. Facial muscles

- **Orbicularis oculi**
- **Orbicularis oris**
- **Zygomaticus**

### 2. Muscles of mastication

- **Masseter**
- **Temporal**



# SKELETAL MUSCLE GROUPS

## A. Muscles of the head and neck

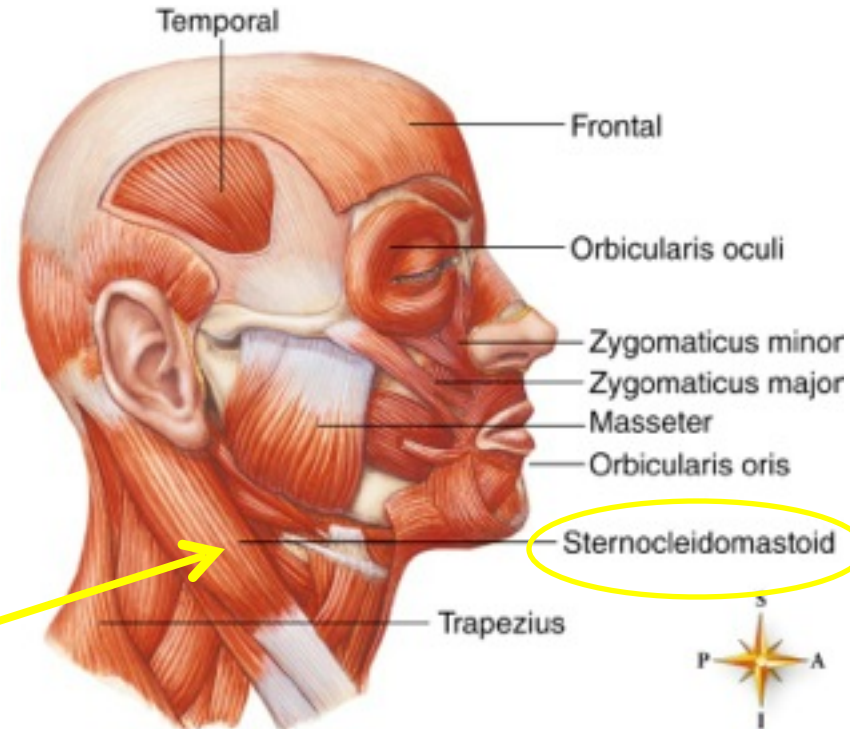
### 1. Facial muscles

- **Orbicularis oculi**
- **Orbicularis oris**
- **Zygomaticus**

### 2. Muscles of mastication

- **Masseter**
- **Temporal**

### 3. **Sternocleidomastoid** — flexes head



# SKELETAL MUSCLE GROUPS

## A. Muscles of the head and neck

### 1. Facial muscles

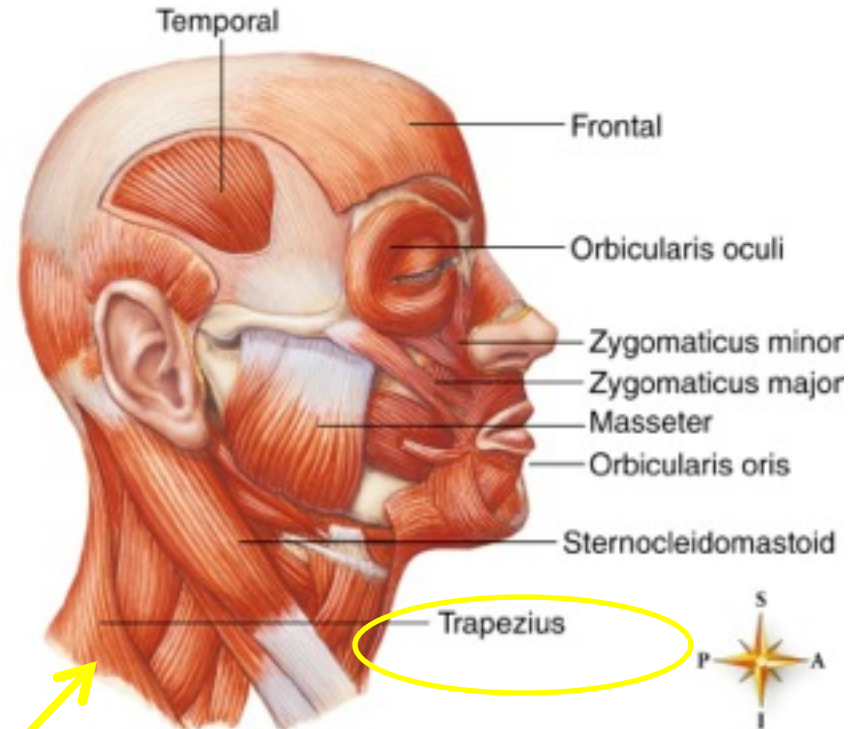
- **Orbicularis oculi**
- **Orbicularis oris**
- **Zygomaticus**

### 2. Muscles of mastication

- **Masseter**
- **Temporal**

### 3. **Sternocleidomastoid** — flexes head

### 4. **Trapezius** —elevates shoulders and extends head



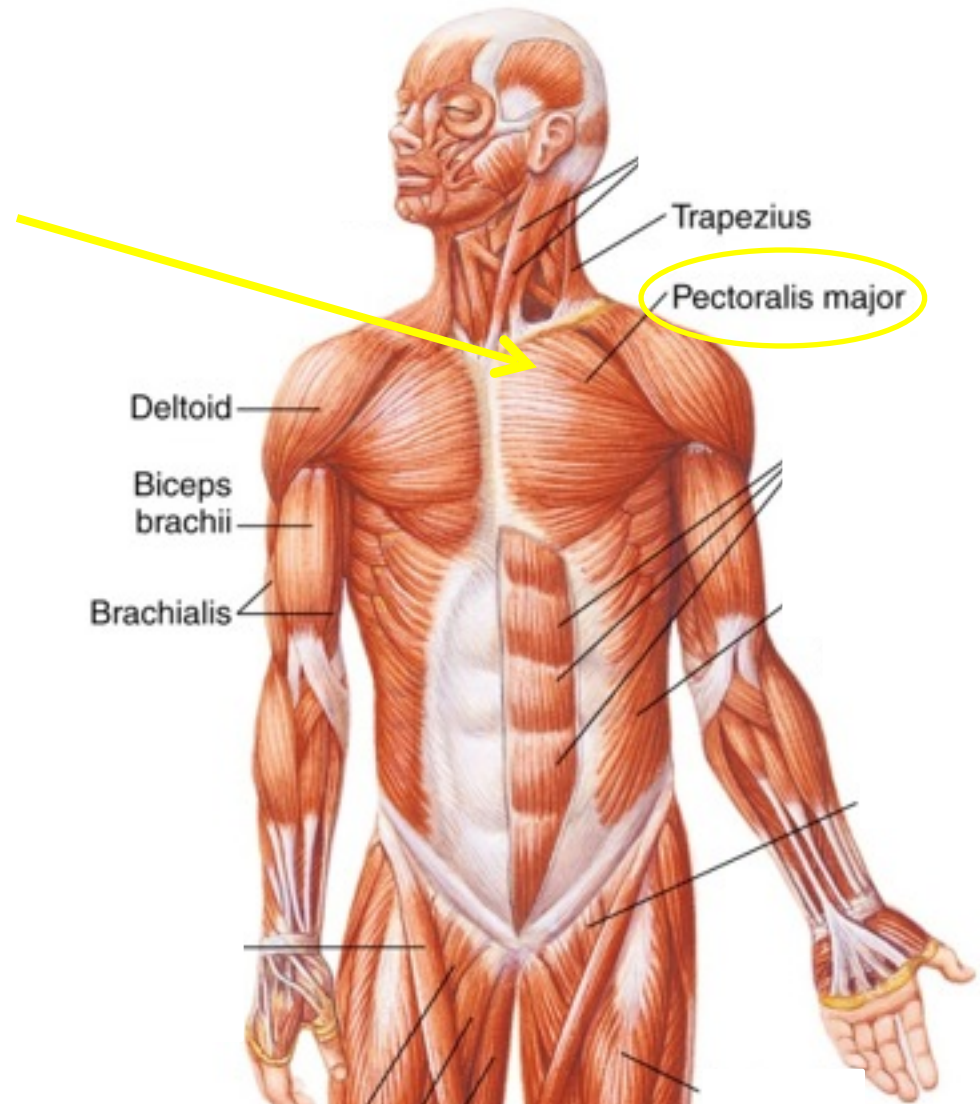


**TABLE 7-1****Muscles Grouped According to Function**

<b>PART MOVED</b>	<b>FLEXORS</b>	<b>EXTENSORS</b>	<b>ABDUCTORS</b>	<b>ADDUCTORS</b>
Upper arm	Pectoralis major	Latissimus dorsi	Deltoid	Pectoralis major and latissimus dorsi contracting together
Lower arm	Biceps brachii	Triceps brachii	None	None
Thigh	Iliopsoas and sartorius	Gluteus maximus	Gluteus medius	Adductor group
Lower leg	Hamstrings	Quadriceps group	None	None
Foot	Tibialis anterior	Gastrocnemius and soleus	Fibularis longus	Tibialis anterior

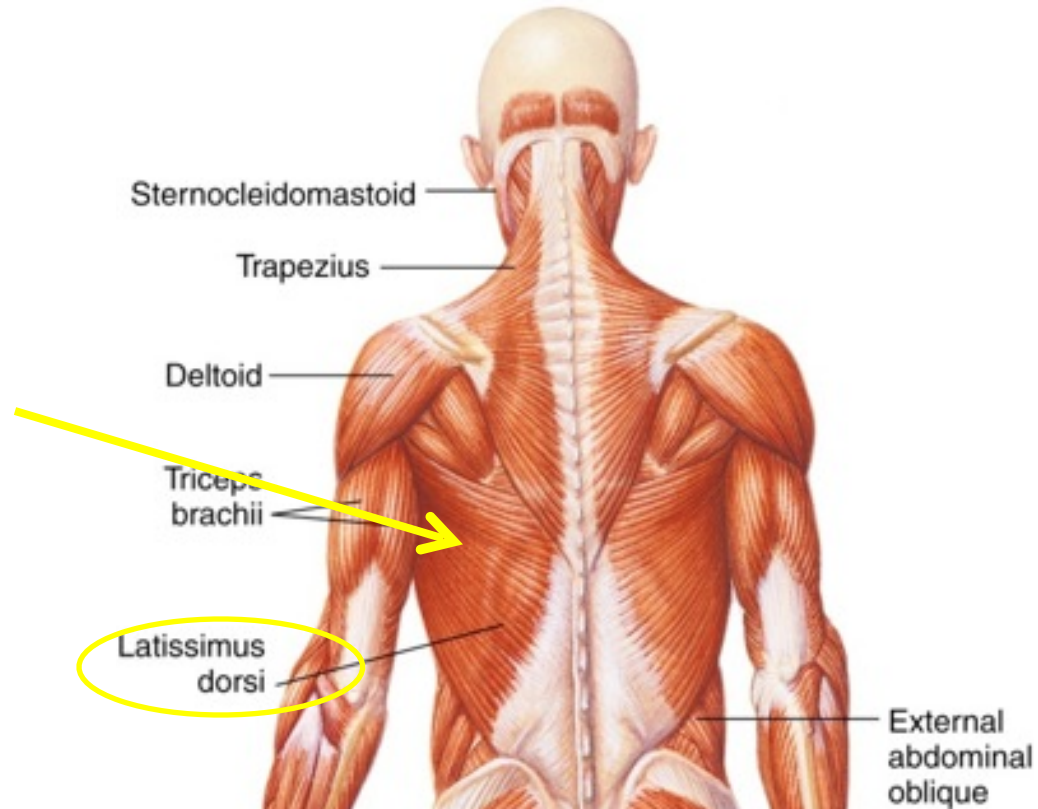
B. Muscles that move the upper extremities

1. **Pectoralis major** — flexes upper arm



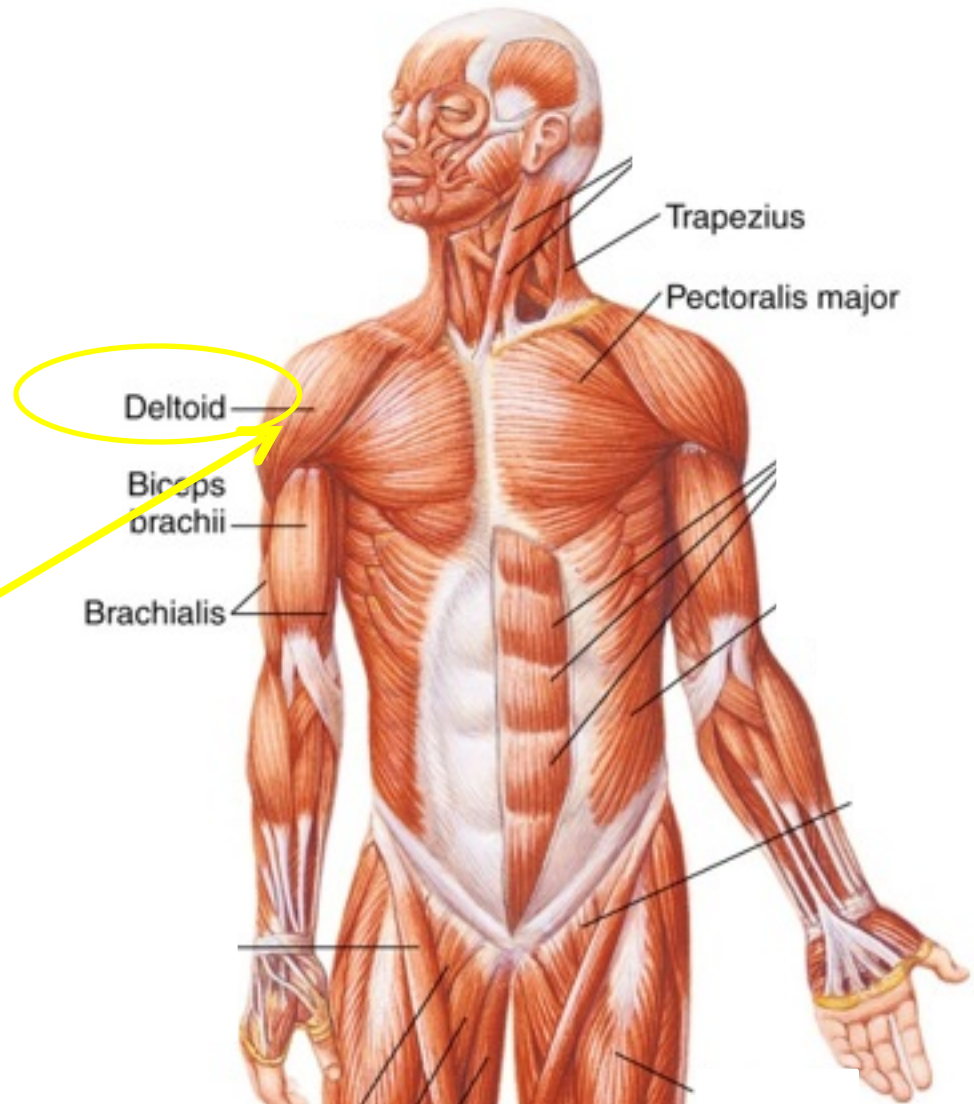
B. Muscles that move the upper extremities

1. **Pectoralis major** — flexes upper arm
2. **Latissimus dorsi** — extends upper arm



B. Muscles that move the upper extremities

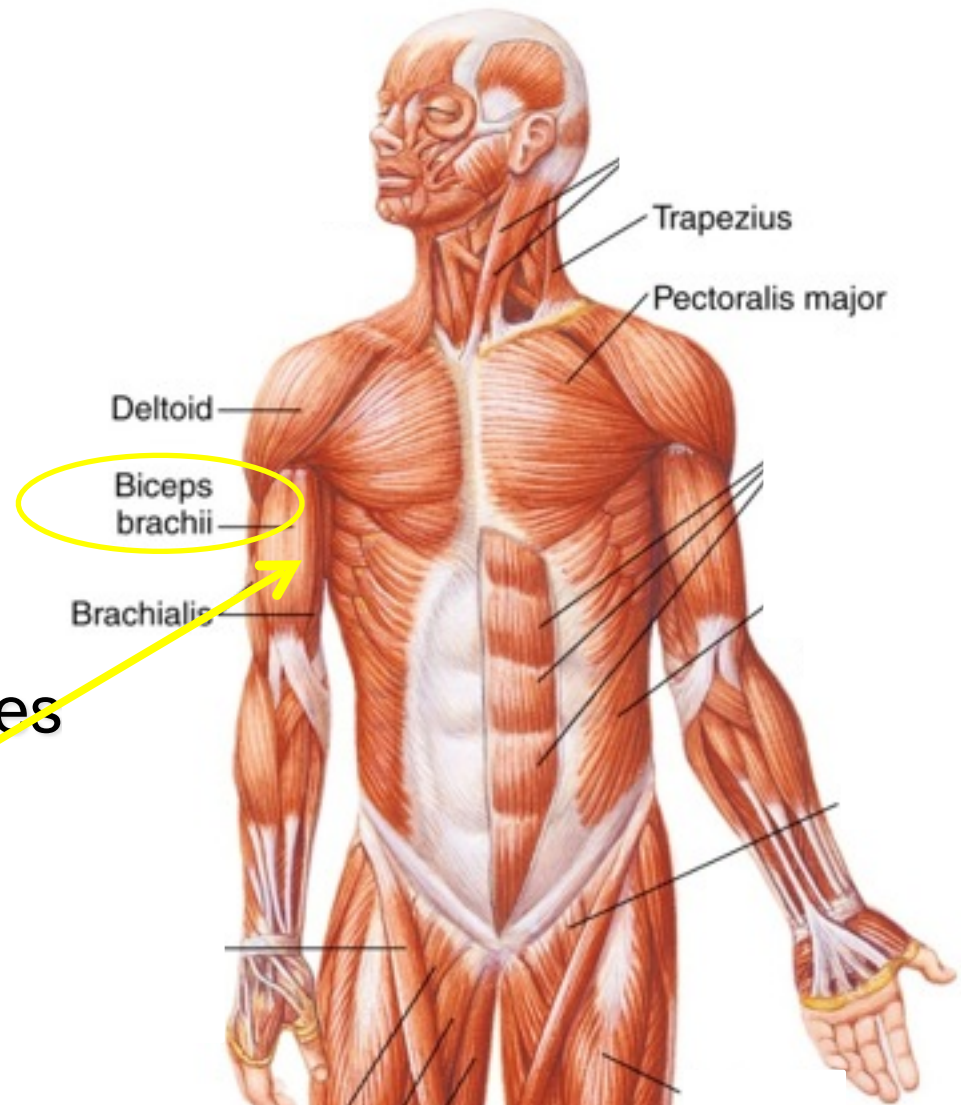
1. **Pectoralis major** — flexes upper arm
2. **Latissimus dorsi** — extends upper arm
3. **Deltoid** — abducts upper arm





B. Muscles that move the upper extremities

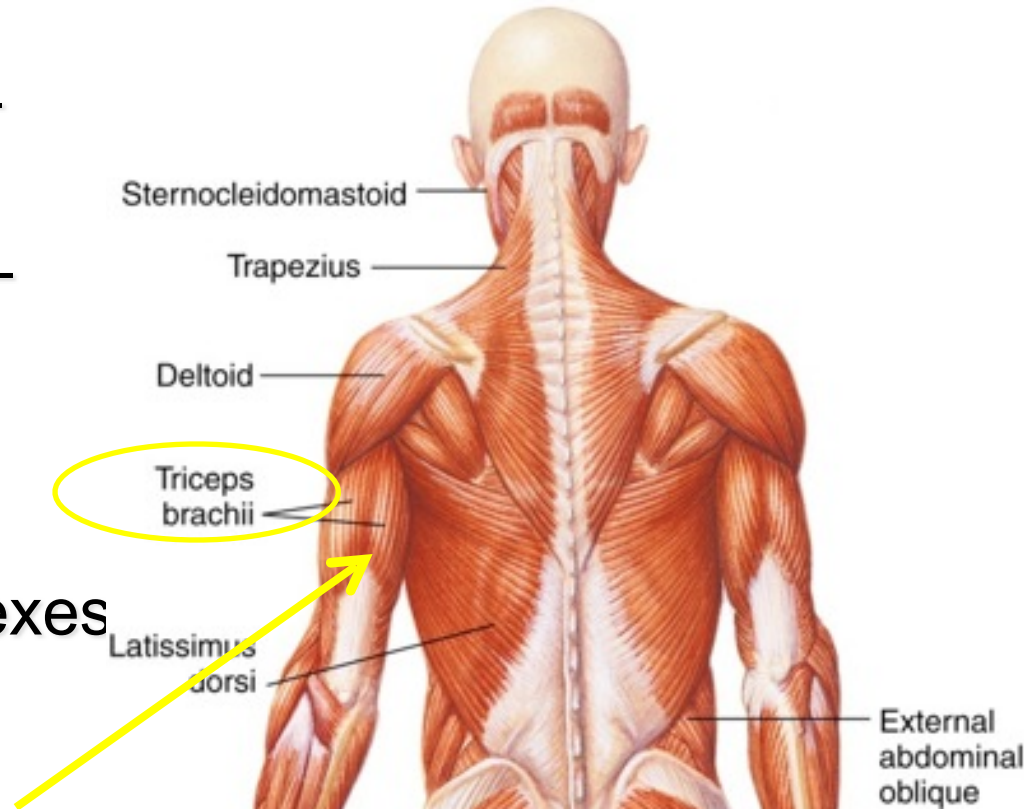
1. **Pectoralis major** — flexes upper arm
2. **Latissimus dorsi** — extends upper arm
3. **Deltoid** — abducts upper arm
4. **Biceps brachii** — flexes forearm



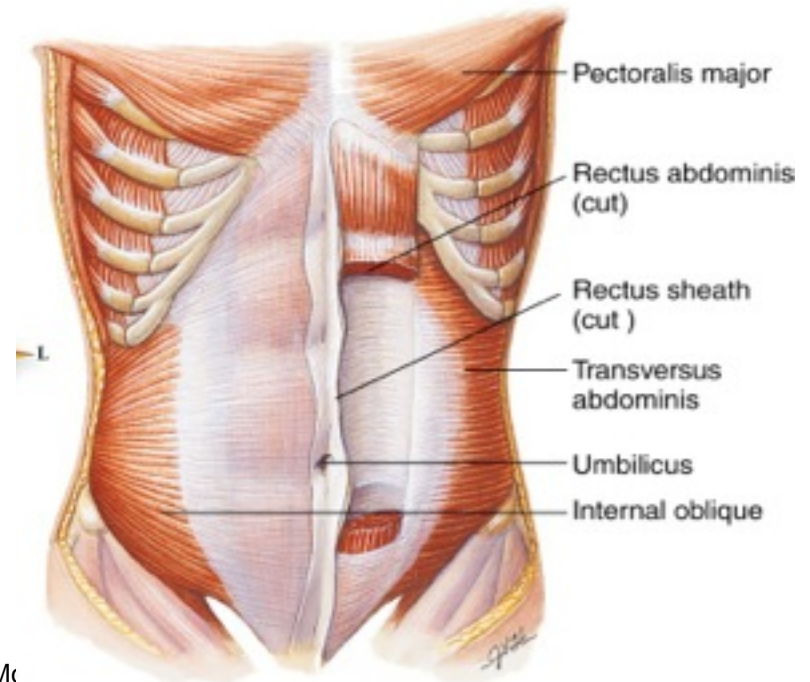
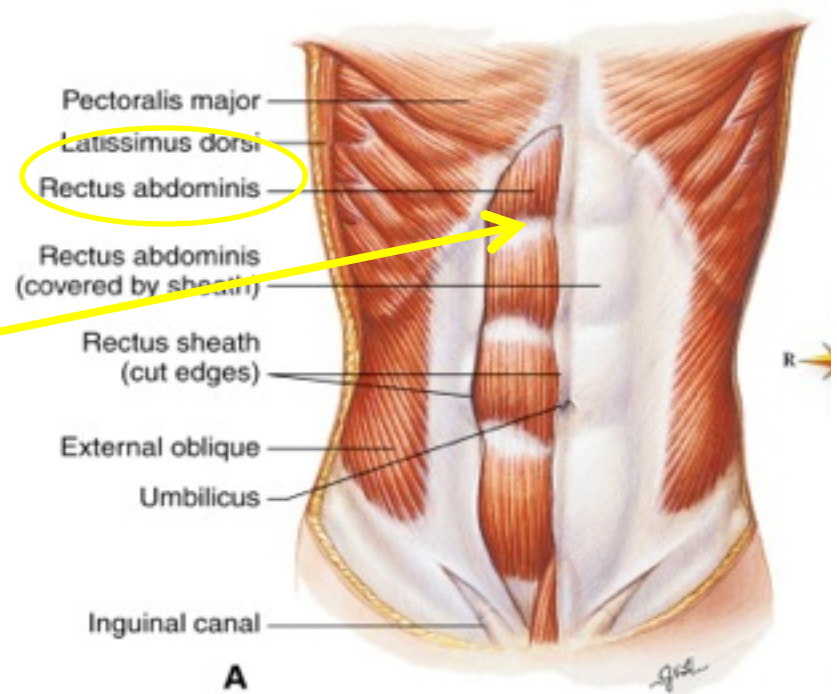


B. Muscles that move the upper extremities

1. **Pectoralis major** — flexes upper arm
2. **Latissimus dorsi** — extends upper arm
3. **Deltoid** — abducts upper arm
4. **Biceps brachii** — flexes forearm
5. **Triceps brachii** — extends forearm



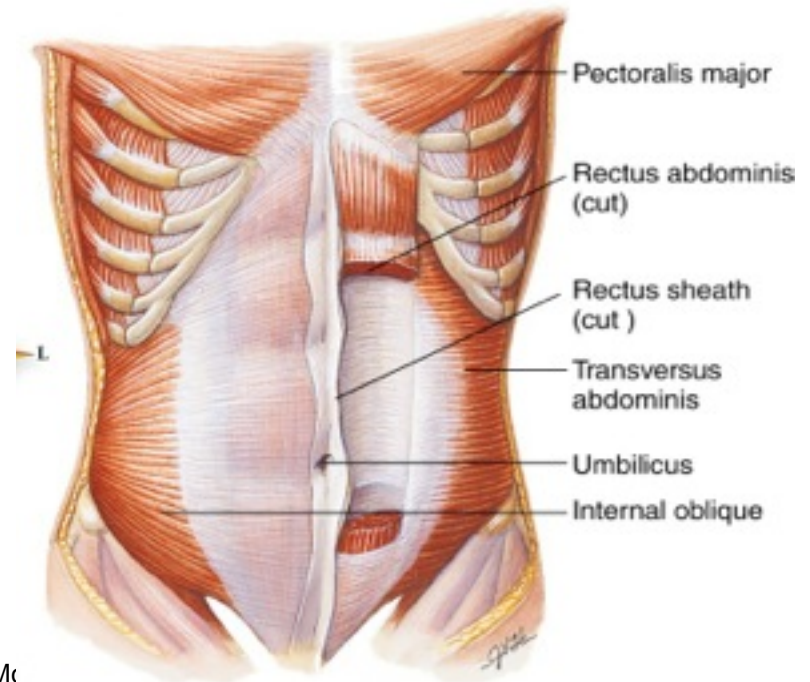
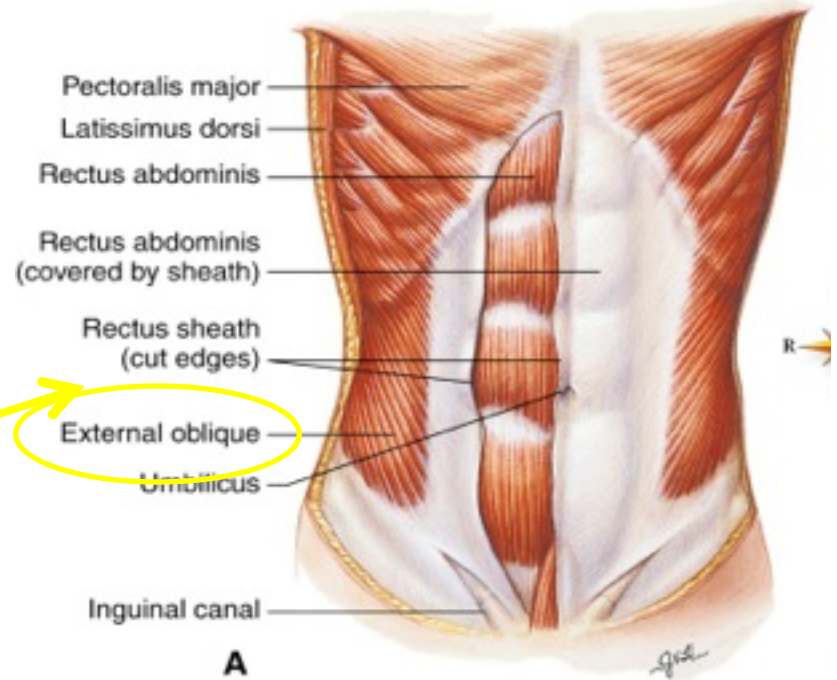
- c. Muscles of the trunk
- 1. Abdominal muscles
  - Rectus abdominis



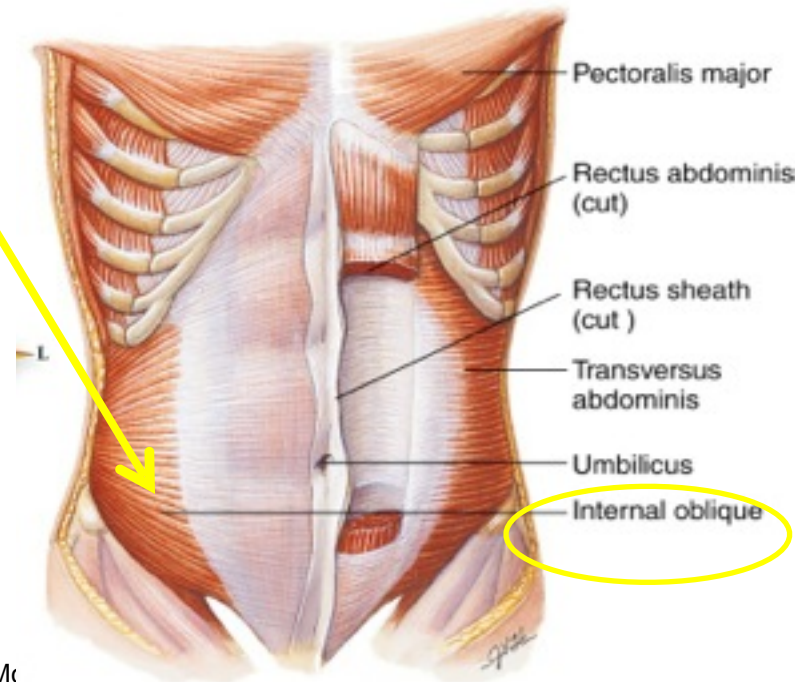
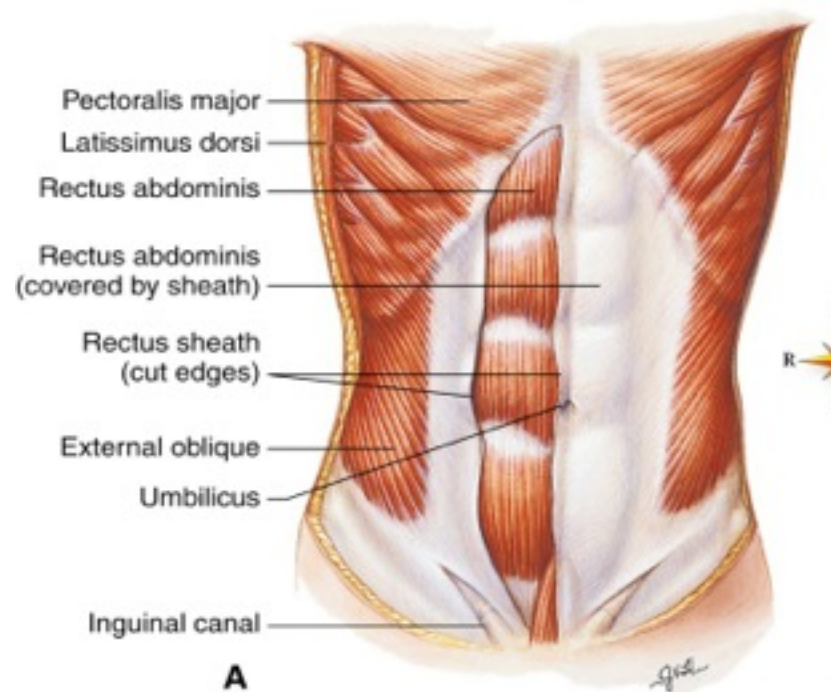
c. Muscles of the trunk

1. Abdominal muscles

- Rectus abdominis
- External oblique



- c. Muscles of the trunk
1. Abdominal muscles
- Rectus abdominis
  - External oblique
  - Internal oblique

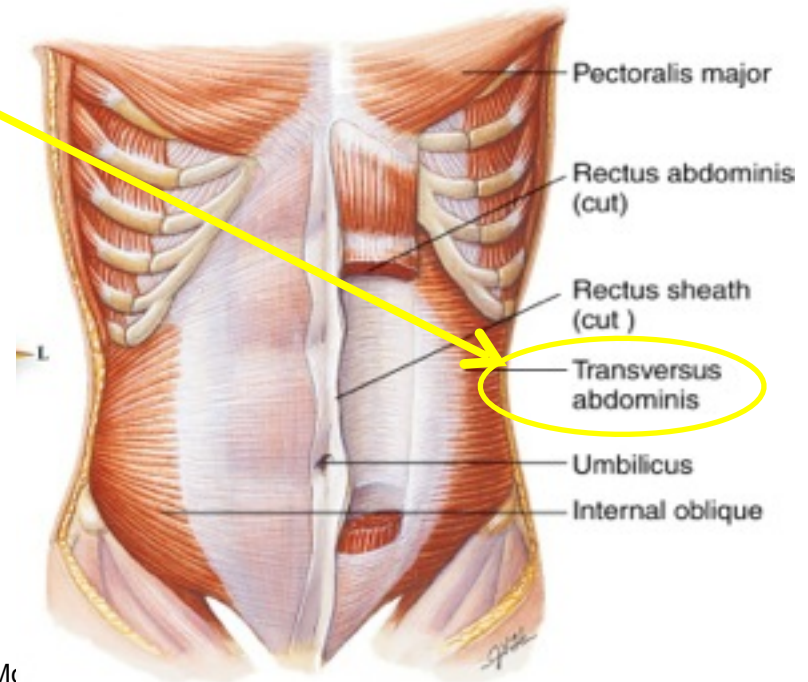
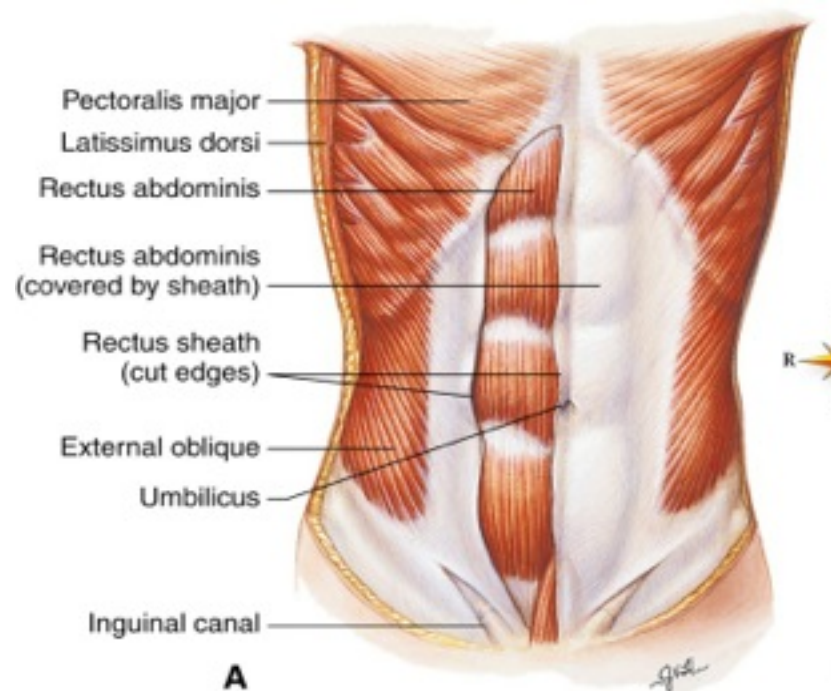




c. Muscles of the trunk

1. Abdominal muscles

- Rectus abdominis
- External oblique
- Internal oblique
- Transversus abdominis





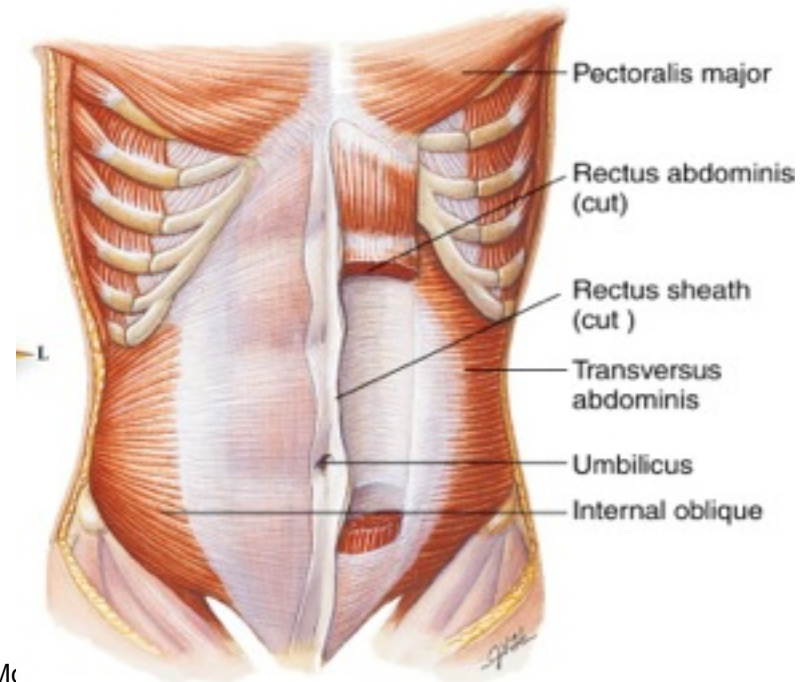
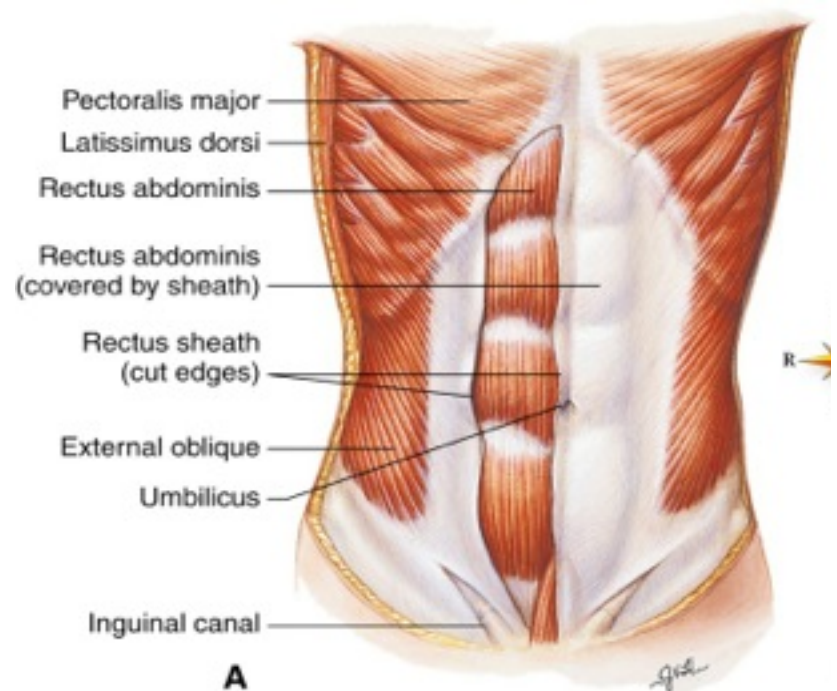
c. Muscles of the trunk

1. Abdominal muscles

- Rectus **abdominis**
- External **oblique**
- Internal **oblique**
- **Transversus** abdominis

2. Respiratory muscles

- **Intercostal** muscles



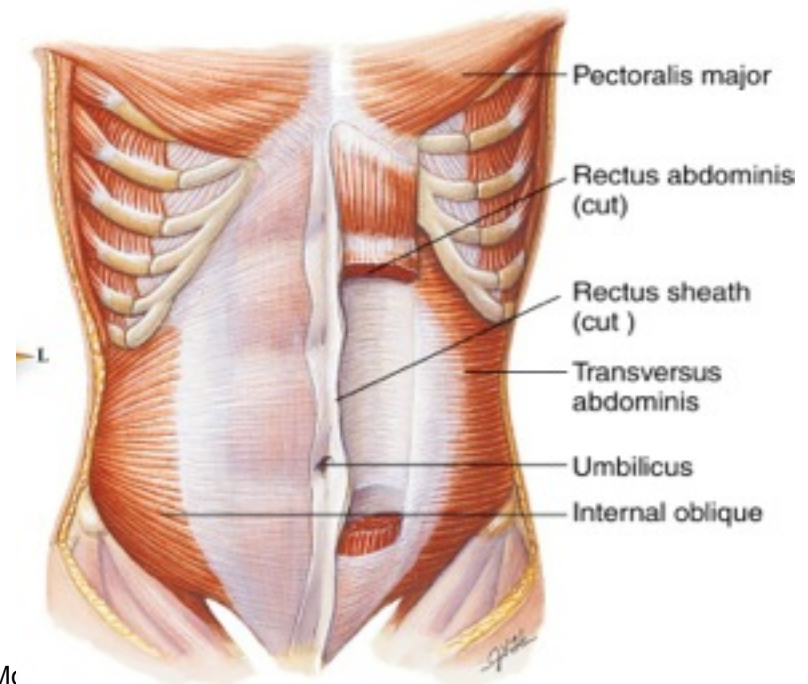
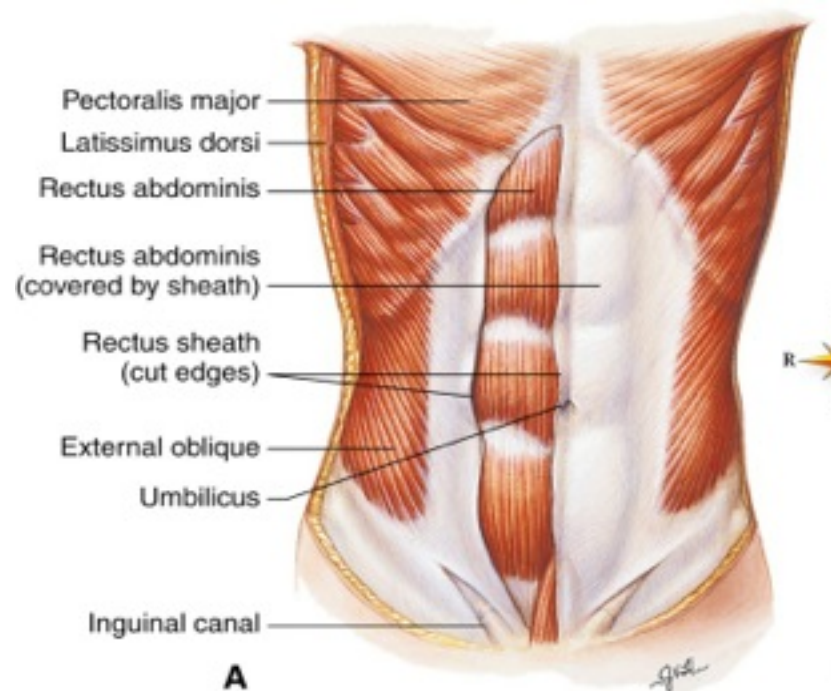
## c. Muscles of the trunk

### 1. Abdominal muscles

- Rectus **abdominis**
- External **oblique**
- Internal **oblique**
- **Transversus** abdominis

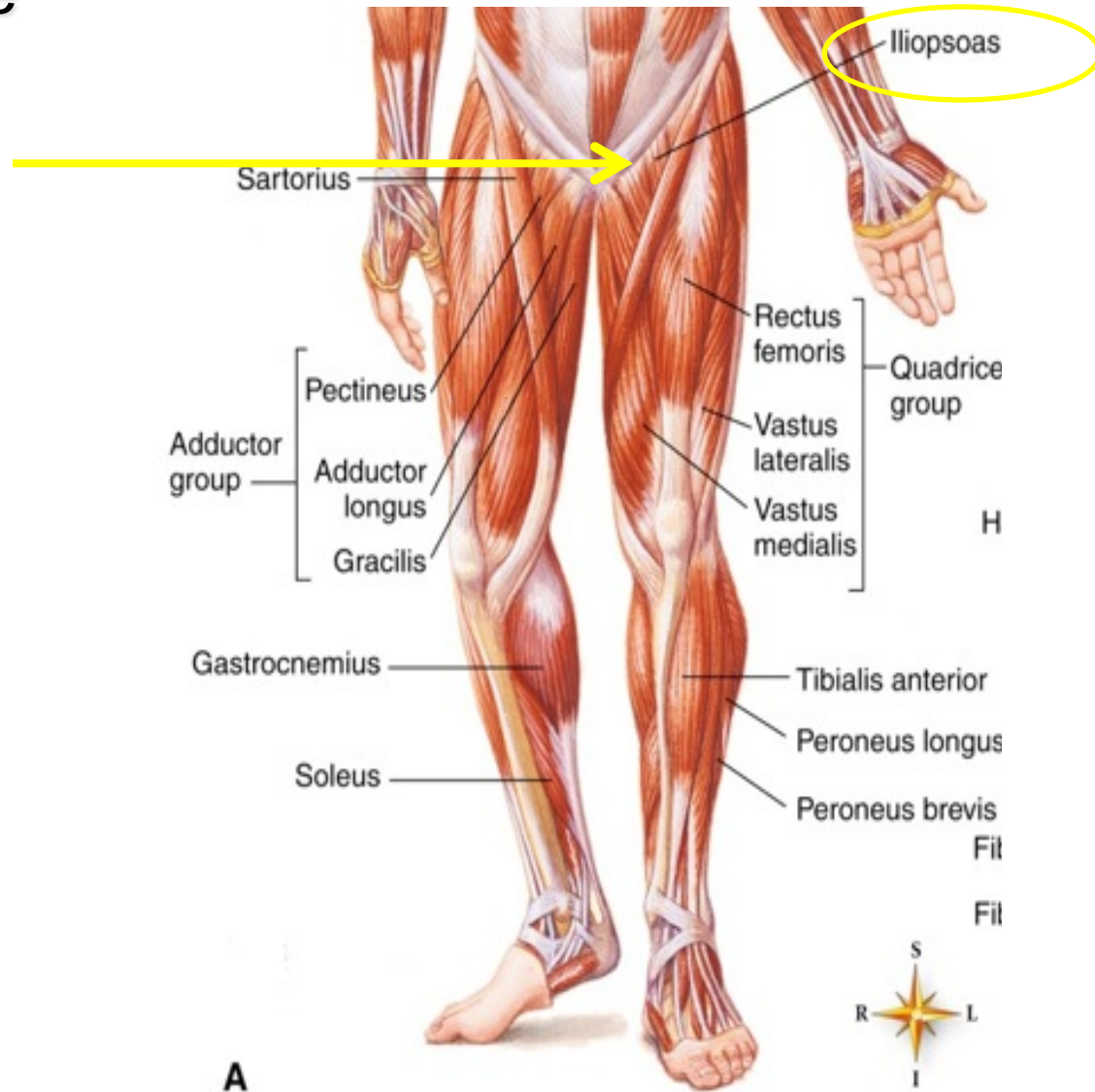
### 2. Respiratory muscles

- **Intercostal** muscles
- **Diaphragm**



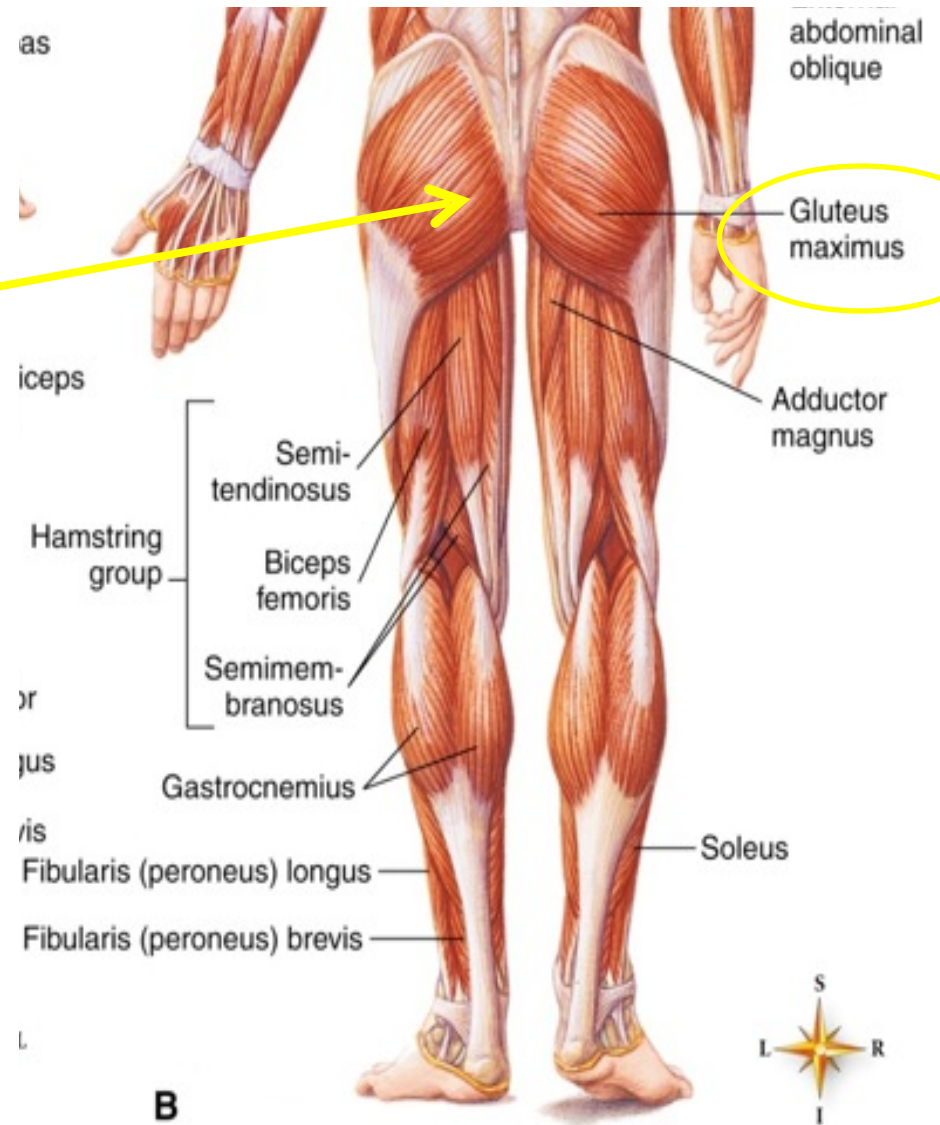
D. Muscles that move the lower extremities

1. **Iliopsoas** —flexes thigh



D. Muscles that move the lower extremities

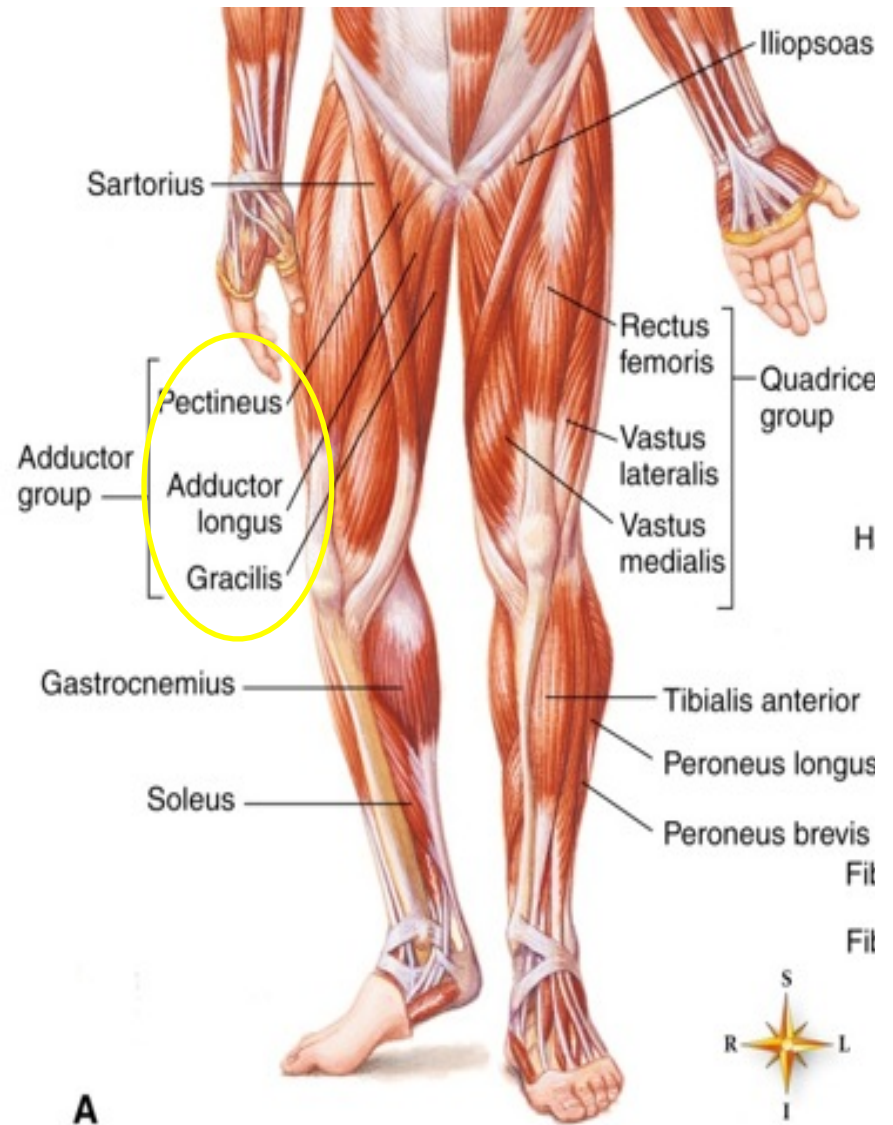
1. **Iliopsoas** —flexes thigh
2. **Gluteus** maximus — extends thigh





D. Muscles that move the lower extremities

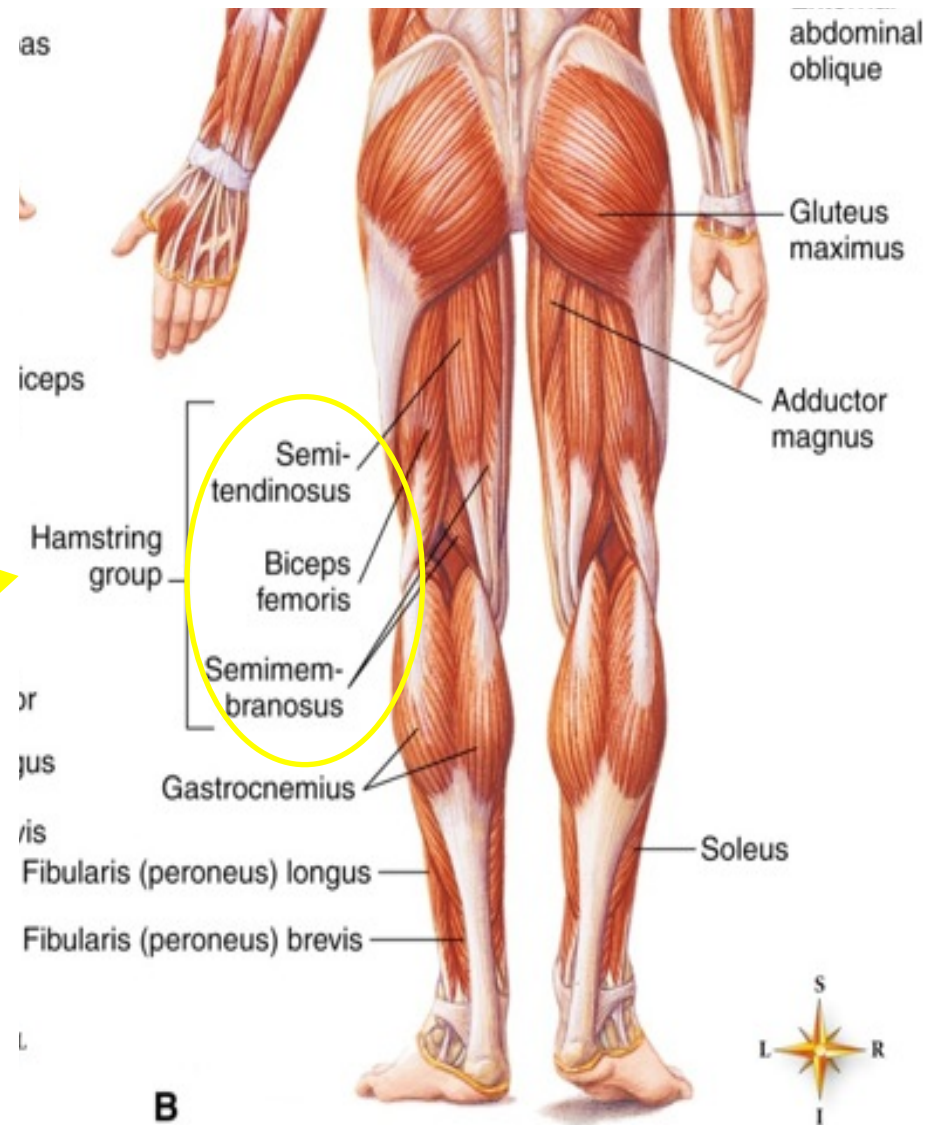
1. **Iliopsoas** —flexes thigh
2. **Gluteus** maximus — extends thigh
3. **Adductor** muscles — adduct thighs





D. Muscles that move the lower extremities

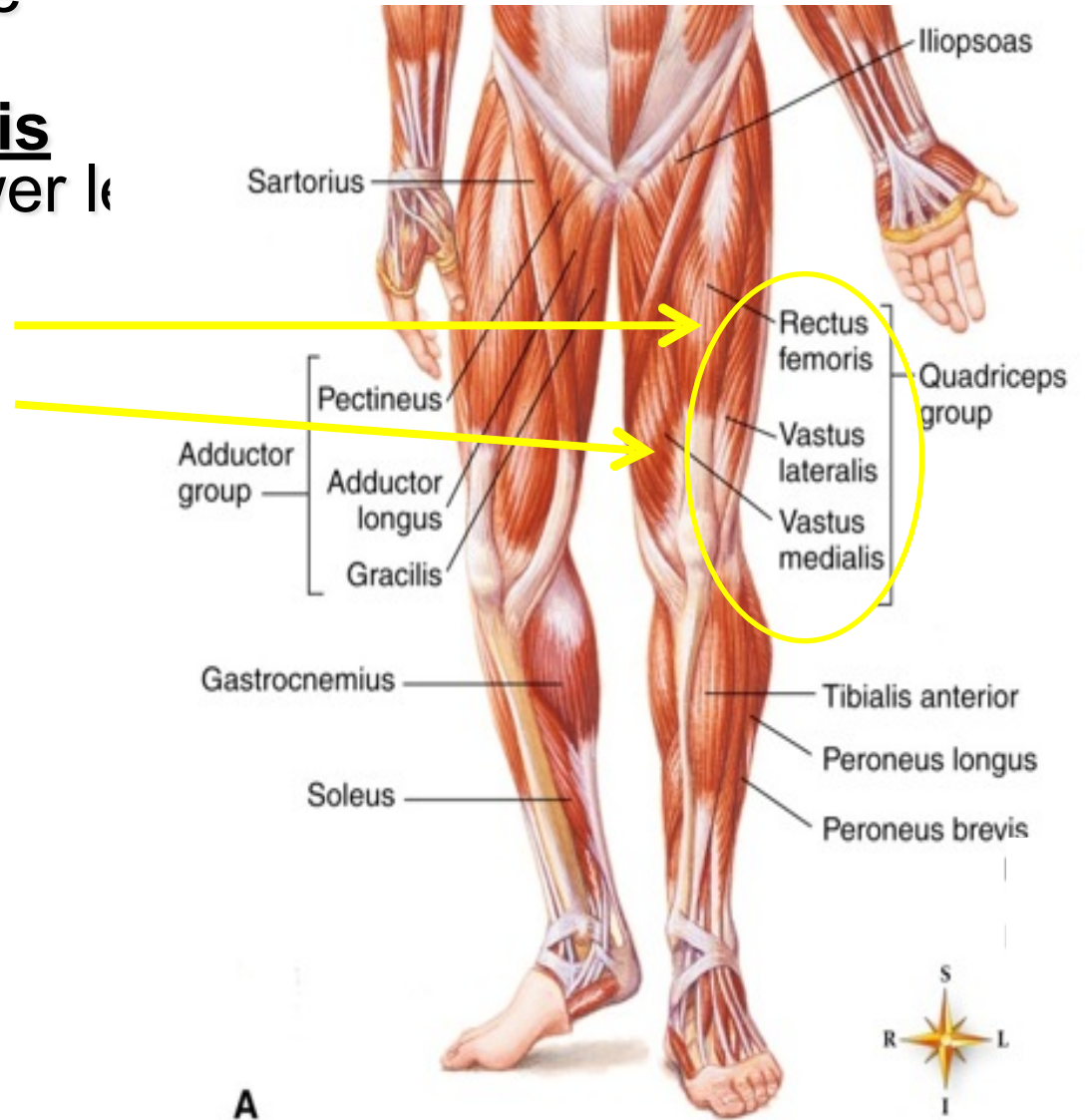
1. **Iliopsoas** —flexes thigh
2. **Gluteus** maximus — extends thigh
3. **Adductor** muscles — adduct thighs
4. Hamstring muscles — flex lower leg
  - **Semimembranous**
  - **Semitendinosus**
  - **Biceps** femoris



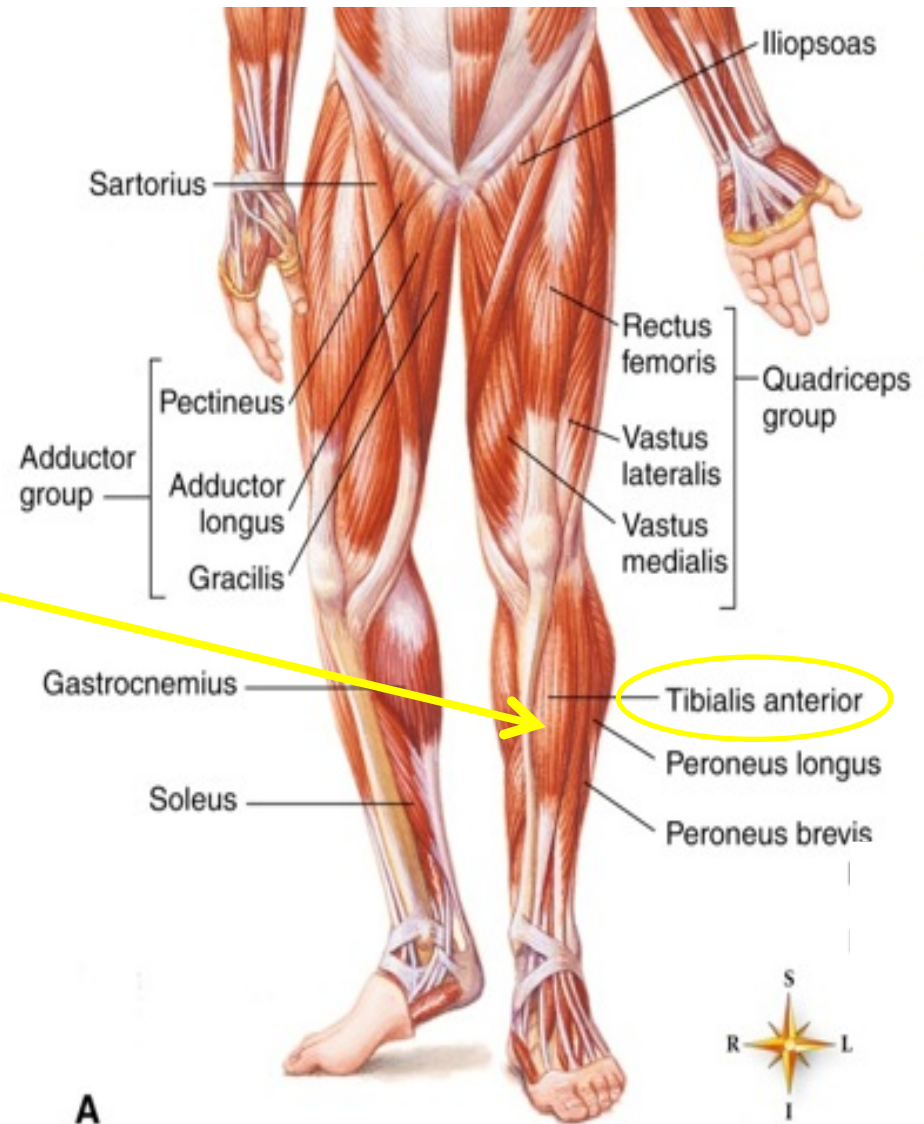
D. Muscles that move the lower extremities

5. Quadriceps femoris group—extend lower leg

- Rectus femoris
- Vastus muscles

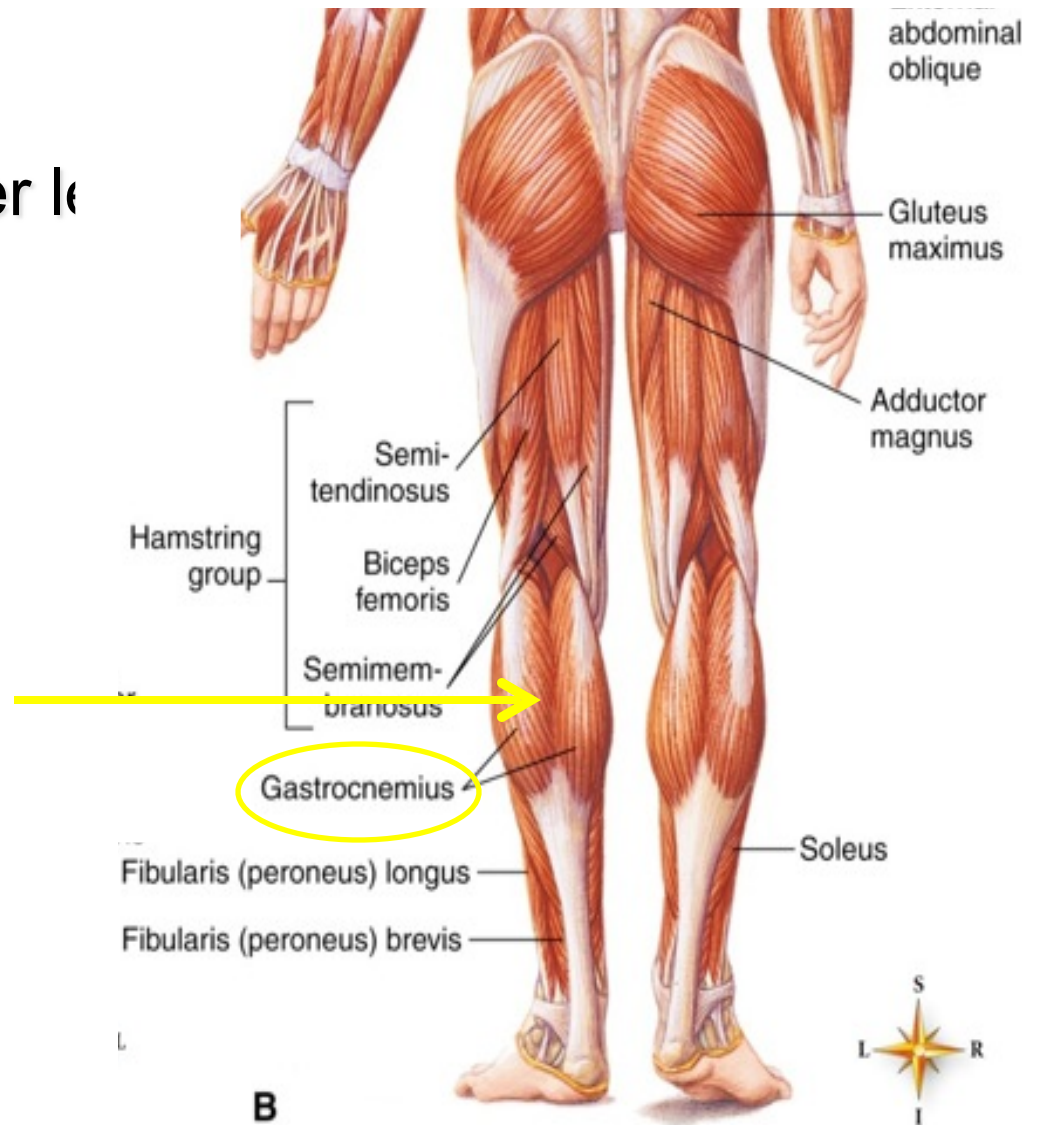


- D. Muscles that move the lower extremities
5. Quadriceps femoris group—extend lower leg
- Rectus femoris
  - Vastus muscles
6. **Tibialis** anterior—dorsiflexes foot



D. Muscles that move the lower extremities

5. Quadriceps femoris group—extend lower leg
  - Rectus femoris
  - Vastus muscles
6. Tibialis anterior—dorsiflexes foot
7. **Gastrocnemius** — plantar flexes foot





D. Muscles that move the lower extremities

5. Quadriceps femoris group—extend lower leg
  - Rectus femoris
  - Vastus muscles
6. Tibialis anterior—dorsiflexes foot
7. Gastrocnemius—plantar flexes foot
8. **Peroneus** group—flex foot

